

# Antimicrobial approach of peri-implant disease: an update of the current knowledge

A.L. Dumitrescu<sup>\*1</sup>, V. Ibric-Cioranu<sup>2</sup>, S. Ibric<sup>2</sup>, N. Zetu<sup>3</sup>, L. Zetu<sup>3</sup> and V. Nicolae<sup>2</sup>

<sup>1</sup>Private practice, str. Politehnicii nr. 3, 060811 Bucharest, Romania

<sup>2</sup>ULBS, Faculty of Medicine, University "Lucian Blaga", 2A Lucian Blaga Street, Sibiu, 550169, Romania

<sup>3</sup>Faculty of Dental Medicine, University of Medicine and Pharmacy "Gr. T. Popa", 16 Universitatii Street, Iasi, 700115, Romania

The success of dental implants depends on many factors, among which the treatment of peri-implant diseases, namely peri-implant mucositis which can subsequently progress to peri-implantitis, play a key role. The main cause of peri-implant disease is accumulation of bacterial plaque on the implant/abutment surface juxtaposed to the junctional epithelium and to the connective tissue zone of the peri-implant soft-tissue unit. The different treatment approaches of peri-implant disease can be categorised into non-surgical and surgical therapies. The non-surgical treatment involves mechanical therapy which can be supplemented with locally and systemically delivered antibiotics. The surgical treatment involves resective and regenerative surgical techniques including the use of bone substitutes and barrier membranes. Both mechanical and chemical decontamination techniques should be applied alongside regenerative surgical procedures to obtain optimum osseointegration and successfully treat peri-implantitis. This chapter reviews the current knowledge in the non-surgical treatment of peri-implant diseases and discusses several antimicrobial treatment protocols.

**Keywords** Peri-implantitis; Peri-mucositis; biofilm; microflora;

## 1. Introduction

The replacement of missing teeth with dental implants has been standard practice in dentistry for many years. Osseointegration or osteointegration refers to a direct bone-to-metal interface without interposition of non-bone tissue [1] and has been defined as: "direct structural and functional onnection between ordered living bone and the surface of a load carrying implant" [2]. Long-term success of dental implants is dependent upon the maintenance of healthy supporting tissues.

### 1.1. Definitions

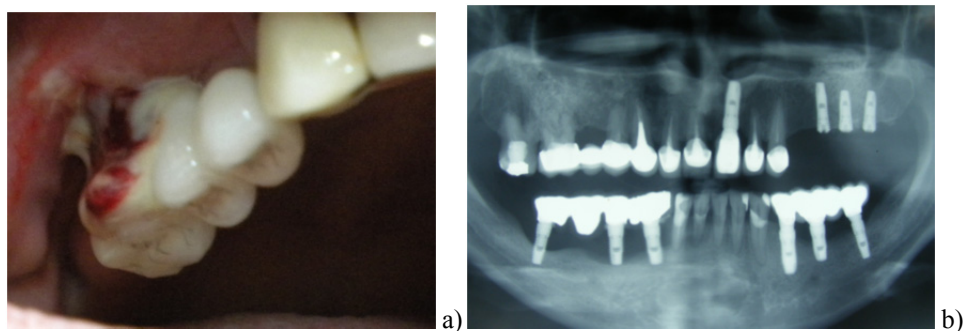
The success of dental implants depends on many factors, among which the treatment of peri-implant diseases, namely peri-implant mucositis which can subsequently progress to peri-implantitis, play a key role. Peri-implant mucositis, defined as a reversible inflammatory reaction in the peri-implant mucosa surrounding an osseointegrated dental implant, corresponds in basic terms of to gingivitis (only plaque-induced gingivitis is addressed in this comparison) [3], without any consideration of the classification of gingivitis (chronic and acute) [4]. Peri-implantitis, defined as an inflammatory reaction associated with loss of supporting bone around the dental implant, basically corresponds to adult periodontitis [5]. Despite similarities regarding clinical features and aetiology of peri-implantitis and periodontitis, critical histopathological differences exist between the two lesions. In human biopsy material it was observed that the apical extension of the inflammatory cell infiltrate was more pronounced in peri-implantitis than in periodontitis and was in most cases located apical of the pocket epithelium. The dominated cells in both types of lesions were plasma cells and lymphocytes, whereas neutrophil granulocytes and macrophages occurred in larger proportions in peri-implantitis. Differences were observed also in experimentally studies, where the placement of ligatures together with plaque formation resulted in loss of supporting tissues around implants and teeth, while following ligature removal, a "self-limiting" process occurred in the tissues around teeth, while in peri-implant tissues the the inflammatory cell infiltrate extended to the bone crest [6].

### 1.2. Prevalence

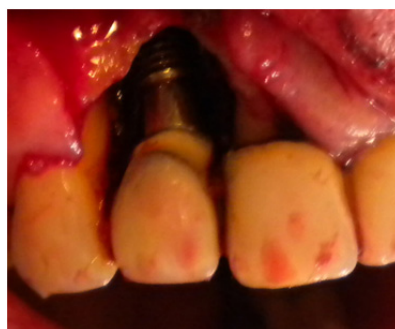There are few cross-sectional studies on patients who have been treated with implants. In 2008 a systematic review revealed that peri-implant mucositis occurred in approximately 80% of the subjects and in 50% of the implants while peri-implantitis was found in 28 -56% of subjects and in 12 - 43% of implant sites [7]. In 2012, the summary of nine studies with 1497 participants and 6283 implants estimates for the frequency of peri-implant mucositis were 63.4% of participants and 30.7% of implants, while those of peri-implantitis were estimated at 18.8% of participants and 9.6% of implant, with a higher frequency of occurrence for smokers (summary estimate of 36.3%) [8].

### 1.3. Diagnosis

Peri-implant lesions may develop after several years, being often asymptomatic. Routine recall appointments and life-long supportive therapy are an absolute necessity for the implant patient [9]. The diagnosis of peri-implant disease requires the regularly assessment of the probing depth, the presence of bleeding on probing, suppuration and evaluation of supporting bone levels around implants with radiographs (**Fig. 1a**) [10]. *Bleeding on probing* indicates the presence of inflammation in the peri-implant mucosa and may be used as a predictor for loss of tissue support as well as for prognostic classification systems of peri-implant mucosal inflammation [3]. *Probing* is essential for diagnosis of peri-implant diseases as an increase in probing depth over time is associated with the loss of attachment and supporting bone [10]. An assessment of *pain on probing* is also considered for prognostic classification systems of peri-implant mucosal inflammation [3]. *The presence of pus*, as the result of infection and an inflammatory lesion, has been found to be associated with progressive peri-implant bone loss [11]. *Clinical mobility* assessment may be performed similar to that for natural teeth by exertion of force by finger or instrument pressure [12]. Additional noninvasive and more sensitive methods to assess subclinical levels of implant mobility include resonance frequency analysis (Osstell; Integration Diagnostics, Sävedalen, Sweden) [13, 14] and damping capacity assessment (Periotest). The two methods are useful and comparably reliable, showing a strong association with each other in assessing implant stability [15]. As the typical peri-implantitis bone defect is well demarcated and circumferential around the implant and the bottom part of the implant retains perfect osseointegration, bone destruction may proceed without any notable signs of implant mobility until osseointegration is completely lost [16]. *The peri-implant crevicular fluid (PICF)*, an osmotically mediated inflammatory exudate, changes in flow rate and profile occur according to the condition of the peri-implant tissue [17], but his analysis is not considered a clinically useful diagnostic parameter for peri-implant disease [9]. *Radiographs* are also required to detect loss of supporting bone; panoramic radiographs cannot replace the periapical radiograph because its level of distortion prevents accurate comparisons (**Fig. 1b**).[10].



**Fig. 1** Peri-implantitis lesions. a) Note the bleeding and suppuration following probing at one of the implants with peri-implantitis; b) Radiograph from six implants exhibiting peri-implantitis, with crater-shaped defects formed in the left side at 2 years after implantation.



**Fig. 2** Peri-implant lesion in the anterior maxillary region. A surgical procedure with a full-thickness flap was performed to expose the affected area.

### 1.4. Classifications

A standardized classification of the peri-implant diseases can serve as the basis upon which both researchers and clinicians may further their knowledge [3]. Disease related to peri-implant mucosal inflammation has been reported as one of the major factors leading to failure of dental implants and a simple prognostic system to help clinicians to foresee the outcomes of peri-implant mucosal inflammation treatment has been proposed by Nogueira-Filho et al. [3]. A classification for peri-implantitis based on the severity of the disease was proposed by Froum and Rosen in aim to facilitate early detection and intervention, the effectively treatment of the disease as well as to help to more accurately determine the exact prevalence of the disease [18]. A combination of bleeding on probing and/or suppuration, probing

depth, and extent of radiographic bone loss around the implant is used to classify the severity of peri-implantitis into early (probing depth  $\geq 4$  mm, bleeding and/or suppuration on probing, bone loss  $< 25\%$  of the implant length), moderate (probing depth  $\geq 6$  mm, bleeding and/or suppuration on probing, bone loss between 25-50% of the implant length), and advanced (probing depth  $\geq 8$  mm, bleeding and/or suppuration on probing, bone loss  $> 50\%$  of the implant length) categories (Fig. 2) [18].

## 2. Etiopathogenesis of peri-implant diseases

### 2.1. Microbiology of peri-implant diseases

The main cause of peri-implant disease is accumulation of bacterial plaque on the implant/abutment surface juxtaposed to the junctional epithelium and to the connective tissue zone of the peri-implant soft-tissue unit [19]. It was showed that the rough implant surfaces were not more prone to colonization by pathogenic bacteria than the smooth surfaces [20]. The analysis with various methods has shown that the microbiota associated with peri-implant disease is (i) mixed, (ii) rather variable, and (iii) in most cases dominated by diverse Gram-negative anaerobic bacteria [16]. Table 1 indicates a microbiological similarity between peri-implant disease and chronic periodontitis, such as *Fusobacterium spp.* and *P. intermedia*, with a difference in the composition of the peri-implant microflora in moderate and advanced peri-implant lesions. However, a lack of marked microbiological differences between the two forms of peri-implant diseases was reported, signifying that in most cases the disease evolves gradually from mucositis to peri-implantitis [16, 19]. More recent reports have showed that a limited number of peri-implantitis cases may harbour a different profile than in chronic periodontitis, but rather similar to the microbiota generally associated with infections of implanted medical devices, with a high numbers of peptostreptococci (i.e. *P. micra*), or staphylococci (i.e. *S. aureus* and *S. epidermidis*) that may colonize implants immediately after placement [21,22]. However, it was previously showed that documented that *S.aureus* can be associated with therapy-resistant (refractory) cases of periodontitis [23-26]. The history of periodontal disease seems to be associated with periimplant disease, the bacteria *Actinobacillus ctinomycetemcomitans*, *Porphyromonas gingivalis*, *Prevotella intermedia*, *Tannerella forsythensis*, and *Treponema denticola* being present in periimplant sites clinically and radiographically characterized, as healthy periimplant tissues, mucositis, and periimplantitis. [27]. As patients with treated generalized aggressive periodontitis were more susceptible to mucositis and peri-implantitis, with lower implant survival and success rates, it has been suggested that the periodontal pockets surrounding teeth may act as a reservoir for microorganisms that colonize the newly inserted implants [28].

**Table 1** Studies on microbiological data from samples taken from peri-implant disease condition

Author	Diagnosis	Identification	Main findings
Mombelli et al. [29]	Peri-implantitis	Culture, Direct phase-contrast microscopy	<i>Actinomyces odontolyticus</i> was first detected at Day 21 and <i>Fusobacterium spp.</i> were first detected at Day 42; at Day 120 small spirochetes were found for the first time, pus formation was noted clinically and a pocket probing depth of 6 mm was recorded.
Mombelli et al. [30]	Failing implants	Culture, Direct phase-contrast microscopy	Unsuccessful sites harbored a complex microbiota with a large proportion of Gram-negative anaerobic rods, Black-pigmented <i>Bacteroides</i> and <i>Fusobacterium spp.</i> Spirochetes, fusiform bacteria as well as motile and curved rods were frequently found in these sites.
Becker et al. [31]	Failing implants	DNA-probe analysis	Moderate levels of <i>Actinobacillus actinomycetemcomitans</i> , <i>Bacteroides intermedius</i> , and <i>Bacteroides gingivalis</i> were detected
Rams et al. [32]	Peri-implantitis	Culture	Periimplantitis lesions exhibited significantly higher proportions of <i>Staphylococci</i> (15.1%) than gingivitis (0.06%) or periodontitis (1.2%) lesions.
Sanz et al. [33]	Diseased sites around implants	Culture	Diseased sites harbored a microbiota with a large number and proportion of Gram-negative anaerobic rods, black-pigmented <i>Bacteroides</i> , and surface translocating bacteria.
Alcoforado et al. [34]	Failing implants	Culture	<i>Peptostreptococcus micros</i> was recovered from 6 failing implants, <i>Wolinella recta</i> from 6, <i>Fusobacterium</i> species from 5, <i>Candida albicans</i> from 5, and <i>Bacteroides intermedius</i> from 4. Enteric rods or pseudomonads constituted a significant part of the microflora in 5 failing implants. <i>Actinobacillus actinomycetemcomitans</i> , nonpigmented <i>Bacteroides species</i> , <i>Capnocytophage</i> species, and <i>staphylococci</i> were detected in a few implant failures.

Rams et al. [35]	Peri-implant infections	Culture, Direct phase-contrast microscopy	<i>Streptococcus sanguis</i> and <i>Streptococcus mitis</i> were the most predominant organisms recovered from clinically stable implants, whereas high proportions of <i>Fusobacterium</i> species and <i>Peptostreptococcus prevotii</i> were isolated from the ailing hydroxyapatite-coated implant.
Rosenberg et al. [36]	Failing implants from infection or trauma	Culture, Direct phase-contrast microscopy	For implants failing with infection, spirochetes and motile rods averaged 42% of total morphotypes. Many suspected periodontopathic organisms including <i>Peptostreptococcus micros</i> , <i>Fusobacterium species</i> , enteric gram-negative rods and yeasts, constituted high proportions of the cultivable microflora. In contrast, implants failing from suspected traumatic etiology demonstrated a morphotype profile consistent with periodontal health and cultivable microflora predominated by streptococci.
Mombelli & Lang [37]	Peri-implant infections	Culture	The implants which showed loss of bone and probing depths $\geq 5$ mm yielded subgingival microbial samples with $\geq 10^6$ CFU/ml, including $\geq 20\%$ gram-negative anaerobic bacteria.
Kalykakis et al. [38]	Implants in maintenance	Latex agglutination assays	<i>Actinobacillus actinomycetemcomitans</i> , <i>Porphyromonas gingivalis</i> , and <i>Prevotella intermedia</i> in subgingival plaque were identified. Sites harboring one of the three microorganisms had significantly greater probing depth, bleeding and crevicular fluid flow rate than non-colonized sites.
Augthun & Conrads [39]	Deep peri-implant bone pockets (> 5 mm)	Culture	The following bacteria dominated: species of the family <i>Bacteroidaceae</i> ( <i>Prevotella intermedia</i> , <i>Prevotella buccae</i> , <i>Prevotella oralis</i> , <i>Prevotella melaninogenica</i> , <i>Prevotella denticola</i> ); <i>Actinobacillus actinomycetemcomitans</i> ; <i>Fusobacterium nucleatum</i> ; <i>Campytophaga spp</i> ; and <i>Eikenella corrodens</i> . <i>Bacteroidaceae</i> and <i>A. actinomycetemcomitans</i> were found particularly frequently. The increased colonization of these bacteria in deep peri-implant bone pockets is consistent with the currently held view of advanced periodontal lesions
Danser et al. [40]	Peri-implantitis in edentulous subjects with a past history of periodontitis	Culture	All subjects harbored <i>Peptostreptococcus spp.</i> , <i>Fusobacterium spp.</i> , and other <i>Prevotella species</i> . <i>Actinomyces odontolyticus</i> , <i>Bacteroides forsythus</i> , <i>Campylobacter rectus</i> , <i>Pseudomonas spp.</i> , and enterobacteria were detected less frequently.
Salcetti et al. [41]	Failing implants	DNA-DNA checkerboard hybridization	A greater detection frequencies of <i>P. nigrescens</i> , <i>P. micros</i> , <i>F. nucleatum ss vincentii</i> , and <i>F. nucleatum ss nucleatum</i> , in mouths with failing implant sites as compared to mouths with healthy control implants
Mombelli et al. [42]	Peri-implantitis	Culture, Direct phase-contrast microscopy	A significant decrease in frequency of detection was noted for <i>Prevotella intermedia/nigrescens</i> , <i>Fusobacterium sp.</i> , <i>Bacteroides forsythus</i> , and <i>Campylobacter rectus</i> after local delivery of tetracycline.
Rutar et al. [43]	History of peri-implantitis	Culture, Direct phase-contrast microscopy	Statistical analysis revealed a significant relationship between periimplant probing depth and the total anaerobic cultivable microbiota as well as the frequency of detection of <i>P. gingivalis</i> .
Hultin et al. [44]	Peri-implantitis	DNA-probe analysis	Patients with peri-implantitis harboured high levels of periodontal pathogens, <i>Actinobacillus actinomycetemcomitans</i> , <i>Porphyromonas gingivalis</i> , <i>Prevotella intermedia</i> , <i>Bacteroides forsythus</i> and <i>Treponema denticola</i> .
Leonhardt et al. [45]	Peri-implantitis	Culture	<i>A. actinomycetemcomitans</i> , <i>P. intermedia</i> , or <i>P. gingivalis</i> were identified in failing implants.
Botero et al. [46]	Peri-implantitis	Culture	<i>P. gingivalis</i> (1.42%) was detected in peri-implant lesions but not in stable implants. The frequency detection of Gram-negative enteric rods (75%) and <i>P. intermedia/nigrescens</i> (25%) was higher in peri-implant lesions ( $P < 0.05$ ).
Covani et al. [47]	Failing implants	Histology of abutment/implant interface	Histologic analysis at the level of abutment/implant interface in 2-stage implants identified heavy bacterial colonization. The bacterial cells were composed of cocci and filaments, which were adherent to the implant surface with an orientation perpendicular to the long axis of the implant.

Persson et al. [48]	Peri-implantitis	DNA–DNA checkerboard hybridization	At Day 10 after local administration of minocycline microspheres (Arestin), lower bacterial loads for 6/40 individual bacteria including <i>Actinomyces gerencseriae</i> , <i>A. israelii</i> , <i>A. naeslundii</i> type 1 and type 2, <i>A. odontolyticus</i> , <i>P. gingivalis</i> and <i>Treponema socranskii</i> were found.
Shibli et al. [49]	Peri-implantitis	DNA–DNA checkerboard hybridization	Higher mean counts of <i>P. gingivalis</i> , <i>T. denticola</i> and <i>T. forsythia</i> were observed in the peri-implantitis group, both supra- and subgingivally.
Emrani et al. [50]	Mucositis	Culture	Microbiological culture of three inflamed peri-implant sites showed an almost identical spectrum of pathogens, including <i>P. gingivalis</i> , <i>T. forsythia</i> , and other major pathogenic bacteria characteristic of aggressive periodontitis.
Maximo et al. [51]	Mucositis and peri-implantitis	DNA–DNA checkerboard hybridization	Levels of <i>T. denticola</i> , <i>T. forsythia</i> and <i>P. micra</i> , and of <i>F. nucleatum</i> , were significantly reduced after peri-implantitis therapy and after mucositis mechanical anti-infective therapy.
Tabanella et al. [52]	Failing implants	Culture	Peri-implant bone loss was associated with the submucosal presence of the putative periodontopathogens <i>T. forsythia</i> , <i>Campylobacter</i> species, and <i>Peptostreptococcus micros</i> . Pain was associated with <i>P. micros</i> , <i>Fusobacterium</i> species, and <i>Eubacterium</i> species.
Persson et al. [53]	Peri-implantitis	Expanded DNA–DNA checkerboard hybridization assay	At selected implant test sites, the most prevalent bacteria were: <i>F. nucleatum</i> sp., <i>Staphylococci</i> sp., <i>A. actinomycetemcomitans</i> , <i>Helicobacter pylori</i> , and <i>T. forsythia</i> . 30 min. after treatment with curettes, <i>A. actinomycetemcomitans</i> (serotype a), <i>Lactobacillus acidophilus</i> , <i>Streptococcus anginosus</i> , and <i>Veillonella parvula</i> were found at lower counts ( $p < 0.001$ ).
Galassi et al. [54]	Peri-implantitis	Culture, real-time PCR, fluorescence resonance energy transfer technology	With all three techniques, <i>P. gingivalis</i> was not very specific for peri-implantitis cases.
Charalampakis et al. [55]	Peri-implantitis	culture and DNA–DNA checkerboard hybridization	Peri-implantitis showed increased number of aerobic Gram-negative bacilli in 18.6% of the patients.
Heuer et al. [56]	Mucositis	PCR technique	A total of 20 different genera were found at the inflamed tooth and implant sites. The microbial diversity of the microflora surrounding the remaining dentition was significantly higher than the diversity of the peri-implant microflora at implant-retained crowns or bridges.
Ebadian et al. [57]	Peri-implantitis	DNA–DNA checkerboard hybridization	Significant differences were observed for <i>T. forsythia</i> , <i>P. intermedia</i> , <i>C. rectus</i> , <i>P. endodontic</i> , <i>P. gingivalis</i> , <i>T. denticola</i> and <i>P. Tannerae</i> .

## 2.2. Main risk factors

Potential risk factors for peri-implant diseases have been addressed by many studies:

### 2.2.1. Poor oral hygiene

Clearly poor oral hygiene is associated with peri-implant mucositis and peri-implantitis and all patients should be advised of both conditions and their need to adopt strict oral hygiene, with obvious attention paid to the gingival margin [5, 58].

### 2.2.2. History of periodontitis:

Patients with treated periodontal disease have increased susceptibility to peri-implantitis especially with regard to aggressive periodontitis [27, 28, 59, 60]. However, also patients with implants replacing teeth lost due to chronic periodontitis demonstrated lower survival rates and more biological complications than patients with implants replacing teeth lost due to reasons other than periodontitis during a 10-year maintenance period [61]. In periodontitis susceptible patients, residual pockets (PPD  $\geq$  5 mm) at the end of active periodontal therapy represent a significant risk for the development of peri-implantitis and implant loss. This may reveal the crucial role of adequate periodontal maintenance in such patients [62]. Analyse of three cohort studies in a recent systematic review showed a higher risk of peri-implantitis in patients with a history of treated periodontitis compared with those without a history of periodontitis (reported odds ratios from 3.1 to 4.7)[63].

### 2.2.3. Cigarette smoking

The possible relationship between smoking and implant failures has been evaluated in several clinical studies [64-70]. Most of the studies report the failure rate of implants in smokers as being more than twice that in nonsmokers. Smoking also has a strong influence on the complication rates of implants, causing significantly more marginal bone loss after implant placement, it increases the incidence of peri-implantitis and affects the success rates of bone grafts. The failure rate of implants placed in grafted maxillary sinuses of smokers is again more than twice that seen in nonsmokers [5,71]. A recent systematic review reported an increased risk of peri-implantitis in smokers compared with nonsmokers (reported odds ratios from 3.6 to 4.6)[62].

### 2.2.4. Diabetes

Diabetes with poor glycemic control, an established risk factor for periodontitis, has been also associated with increased incidence of peri-implant disease [72].

### 2.2.5. Genetic traits:

Cytokine gene polymorphisms may modulate the host response to the bacterial challenge and influence susceptibility to peri-implantitis. Many studies document that IL-1 polymorphism alone cannot be considered a risk factor for bone loss, but in combination with smoking, it is closely associated with periimplant bone loss [73]. However, at the present time routine genetic testing for the assessment of the risk of peri-implantitis cannot be recommended as a standard of care at this time [74].

### 2.2.6. Implant surface

Implant surfaces are commonly classified into four categories depending on surface roughness values as: smooth, minimally rough, moderately rough or rough [75, 76], with the majority of marketed implants having moderately rough surfaces ( $S_a$  between 1.0 and 2.0  $\mu\text{m}$ ), which is optimal for bone healing response [77]. Presently only a few studies provided data on how implant surfaces influence peri-implant disease with no evidence that implant surface characteristics can have a significant effect on the initiation of peri-implantitis [78].

### 2.2.7. Implant placement-related factors

Cement-retained fixed implant-supported restorations involve the risk of excess cement, which can associate peri-implantitis [79-82]. In a recent retrospective study, methacrylate cement residues (Premier Implant Cement, Premier® Dental Products Company, Plymouth Meeting, PA, USA) were identified in 59.5% of the implants, being associated with bleeding on probing and suppuration. After removal of the excess cement and recementation with Temp Bond (Kerr Sybron Dental Specialities, Washington, D.C., USA), a 76.9% reduction in bleeding on probing was found at follow-up [83].

### 2.2.8. Width of keratinized peri-implant mucosa

Whether or not keratinized tissue is needed around dental implants to maintain peri-implant health is a controversial subject. Several studies suggested that the absence of keratinized mucosa around dental endosseous implants increases the susceptibility of the peri-implant region to plaque-induced tissue destruction while increased width of keratinized mucosa around implants is associated with lower mean alveolar bone loss and improved indices of soft tissue health [84-87]. However, a recent systematic review stated that: „(i) the width of keratinized tissue did not influence the survival rate of dental implants; (ii) there is no evidence to recommend a specific technique to preserve/augment keratinized tissue; and (iii) factors including bone level, keratinized tissue and implant features have not been shown to be associated with future mucosal recession around dental implants“ [88].

### 2.2.9. Occlusal factors

In human clinical studies, the role occlusal force as a risk factor in development and progress of peri-implant disease is yet unclear [89] even if it was suggested that occlusal overload on implants may increase the incidence of marginal bone loss [90, 91]. Overloading factors that may negatively influence on implant longevity include large cantilevers, parafunctions, improper occlusal designs, and premature contacts [92]. In animal studies it has been showed that occlusal overload may lead to bone loss in the presence of dental plaque and to an increase in bone density in areas where plaque control is performed [93].

### 3. Treatment options

#### 3.1. Periodontal infection control including plaque control regimens and mechanical instrumentation

Antimicrobial oral mouth rinses in combination with mechanical treatment may be effective in the treatment of mucositis [94, 95], while the non-surgical approaches to peri-implantitis demonstrated limited improvements [96].

#### 3.2. Administration of local and systemic antimicrobials as an adjunct to mechanical and surgical therapy

In peri-implantitis lesions non-surgical therapy alone was not found to be effective [94, 95] and the adjunctive chlorhexidine application had only limited effects on clinical and microbiological parameters [95]. Adjunctive chlorhexidine gel application did not enhance the results compared with mechanical cleansing alone [97]. As showed in Tables 2 and 3, adjunctive local or systemic antibiotics were shown to reduce bleeding on probing and probing depths [94, 98]. It was revealed that peri-implantitis patients frequently yielded submucosal bacterial pathogens resistant in vitro to individual therapeutic concentrations of clindamycin, amoxicillin, doxycycline, or metronidazole, but only rarely to both amoxicillin and metronidazole [99]. Both mechanical and chemical decontamination techniques should be applied alongside regenerative surgical procedures to obtain optimum re-osseointegration and successfully treat peri-implantitis [100].

**Table 2** Studies on systemic antimicrobials in the treatment of peri-implantitis

Author	Treatment	Study length	Main findings
Mombelli & Lang [101]	Mechanical cleaning, irrigation of all peri-implant pockets > 3 mm with 0.5% chlorhexidine and systemic antimicrobial therapy (1000 mg ornidazole for 10 consecutive days).	1 year	Reduction of bleeding scores and probing depths
Khoury & Buchmann [102]	Flap surgery + autogenous bone grafts alone or plus non-resorbable (or bioabsorbable barriers + systemic antibiotics	3 years	At the 3-year visit, surgical treatment revealed significant changes from baseline for the controls and both of the test groups for probing depths, probing bone levels, mobility scores and intrabony defect height
Leonhardt et al. [103]	Surgical exposure of the lesions and cleaning of the implants using hydrogen peroxide were performed. The patients were given systemic antibiotics according to a susceptibility test of target bacteria	5 years	58% of the implants were successfully treated; 27% were lost
Charalampakis et al. [104]	Bone plasty in conjunction to antibiotics during surgery	9 years	In 54.7% of the patients it was not possible to arrest progression of peri-implantitis
Heitz-Mayfield et al. [105]	Open flap debridement and implant surface decontamination, with adjunctive systemic amoxicillin and metronidazole	1 year	At 12 months all treated implants had a mean probing depth < 5 mm with no bleeding in 47% of the implants. Overall a 100% survival of treated implants with 92% of implants having stable crestal bone levels or bone gain.

**Table 3** Studies on local antimicrobials in the treatment of peri-implantitis

Author	Treatment	Study length	Main findings
Mombelli et al. [106]	Mechanical Debridement + tetracycline fibers 10 days	1 year	Two patients were discontinued from the study after 180 days because of persisting active peri-implantitis with pus formation. The remaining subjects showed a significant decrease of mean peri-implant probing depth, reduced bleeding tendency and a significant decrease in frequency of <i>P. intermedia</i> , <i>Fusobacterium sp.</i> , <i>B. forsythus</i> , and <i>C. rectus</i> .

Büchter et al. [107]	Instruction in oral hygiene + implant scaling with a hand plastic instrument + randomly allocation to continue with this treatment or to have in addition mechanical debridement and local application of 8.5% doxycycline hyclate (Atridox)	18 weeks	Only subjects treated with Atridox had a significant gain in mean bleeding on probing, gain in mean probing attachment levels and a significant reduction in pocket probing depths.
Renvert et al. [108]	Oral hygiene instruction + supra- and submucosal scaling + Rubber cup Polishing + subgingival antimicrobial treatment using either chlorhexidine gel 1% 1ml or minocycline microspheres	3 months	The combined mechanical/antimicrobial treatment for the chlorhexidine group did not result in any reduction in probing depth and showed only limited reduction of bleeding scores.
Renvert et al. [109]	Oral hygiene instruction + supra- and submucosal scaling + Rubber cup Polishing + subgingival antimicrobial treatment using either chlorhexidine gel 1% 1ml or minocycline microspheres	1 year	The adjunctive use of minocycline microspheres resulted in improvements of probing depths and bleeding scores, whereas the adjunctive use of chlorhexidine resulted in only limited reduction of bleeding scores
De Araújo Nobre et al. [110]	Mechanical cleaning +Oral hygiene instruction + 0.2% CHX gel with plastic needle (repeated after 2 weeks)	1 year	Treatment success was achieved in eight of the nine patients (and in 11 of the 13 implants)
Salvi et al. [111]	Oral hygiene instruction + mechanical debridement+ 0.2% chlorhexidine gel + Minocycline microspheres (Arestin)	1 year	Six implants out of 31 were either rescued or exited because of persisting active peri-implantitis. Successful implants showed a statistically significant reduction in both probing depth and bleeding on probing.
Renvert et al. [112]	Minocycline microspheres or 0.1% chlorhexidine gel	1 year	The use of minocycline resulted in significant improvements in probing depths compared to chlorhexidine at days 30, 90, and 180 but not at 12 months
Sahm et al. [113]	Oral hygiene program (OHI) then instrumenredented using either (1) AAD (amino acid glycine powder) or (2) mechanical debridement using carbon curets and antiseptic therapy with chlorhexidine (MDA).	6 months	Both treatment procedures resulted in comparable but limited clinical attachment level (CAL) gains at 6 months ( $0.4 \pm 0.7$ mm versus MDA: $0.5 \pm 0.8$ mm). OHI+AAD was associated with significantly higher bleeding on probing (BOP) reductions than OHI+MDA

### 3.4. Laser therapy

In recent years, lasers and photodynamic therapy have been investigated as methods for reducing bacteria on implant surfaces [97]. Finally, as no reliable method has been identified to successful treat peri-implantitis, the early detection and regular maintenance plays a principal role in reducing the occurrence of this inflammatory and destructive disease [98]. As showed in Table 4, minor beneficial effects of laser therapy compared with conventional mechanical therapy on peri-implantitis have been shown [114].

**Table 4** Studies on laser therapy in the treatment of peri-implantitis

Author	Treatment	Study length	Main findings
Schwarz et al. [115]	(1) Er:YAG laser (100 mJ/pulse), or (2) mechanical debridement using plastic curettes and antiseptic therapy with chlorhexidine digluconate (0.2%) (C).	6 months	Er:YAG laser resulted in a statistically significant higher reduction of bleeding scores than C. No statistically significant difference regarding mean clinical attachment level changes, after 6 months.
Schwarz et al. [116]	Nonsurgically instrumented using either (1) an Er:YAG laser (100 mJ/pulse, 10 Hz) device or (2) mechanical debridement using plastic curettes and antiseptic therapy with chlorhexidine digluconate (0.2%) (C).	1 year	Er:YAG laser resulted in a significantly higher bleeding scores reduction than C, but its effectiveness seemed to be limited to a period of 6 months, particularly at advanced periimplantitis lesions.



Schwarz et al. [117]	A single episode of non-surgical instrumentation using Er:YAG laser (12.7 J/cm <sup>2</sup> )	2 years	Improvements of all clinical parameters investigated. However, histo-pathological examination of tissue biopsies revealed a mixed encapsulated chronic inflammatory cell infiltrate and increased proliferation of vascular structures.
Person et al. [118]	One time treatment with an Er:YAG laser or an air-abrasive device	6 months	Modest probing depth reductions not significantly different in the two groups (0.9 ± 0.8 mm and 0.8 ± 0.5 mm)
Schwarz et al. [119]	Flap surgery then randomly allocation to surface debridement/decontamination using either (i) an Er:YAG laser device, or (ii) plastic curets+cotton pellets+sterile saline (CP).	6 months	At 6 months, Er:YAG laser treated sites failed to reveal higher reductions in mean bleeding on probing (47.8 ± 35.5 versus 55.0 ± 31.1%) and clinical attachment level values (1.5 ± 1.4 versus 2.2 ± 1.4 mm) when compared with the control group
Schwarz et al. [120]	Access flap surgery, then either (i) an Er:YAG laser (ERL) device, or (ii) plastic curets + cotton pellets + sterile saline (CPS) augmented with a natural bone mineral and covered with a collagen membrane.	2 years	At 24 months, Er:YAG laser treated sites failed to reveal significantly higher reductions in mean bleeding scores and clinical attachment level values when compared with the CPS group. In both groups, after 2 years, mean clinical attachment level values were not significantly different when compared with baseline.

A recent systematic review has been performed in aim to identify the most effective interventions for treating peri-implantitis around osseointegrated oral implants. Unfortunately, follow-up longer than 1 year suggested recurrence of peri-implantitis in up to 100% of the treated cases for some of the tested interventions [121].

#### 4. Conclusion

Treatment of peri-implantitis is extremely challenging and difficult. In aim to allow early diagnosis of peri-implant disease, at least, annual monitoring of the peri-implant probing depths and the presence of bleeding on probing and suppuration must be performed to allow comparisons with the baseline recordings. For the high risk patients a strict maintenance programme should be adopted, with the recommendation to visit a hygienist at least every 3 months.

#### References

- [1] Mavrogenis AF, Dimitriou R, Parvizi J, Babis GC. Biology of implant osseointegration. *J Musculoskelet Neuronal Interact.* 2009;9:61-71.
- [2] Brånemark PI. Osseointegration and its experimental studies. *J Prosthet Dent.* 1983;50:399-410.
- [3] Nogueira-Filho G, Iacopino AM, Tenenbaum HC. Prognosis in implant dentistry: a system for classifying the degree of peri-implant mucosal inflammation. *J Can Dent Assoc.* 2011;77:b8.
- [4] Lang NP, Bosshardt DD, Lulic M. Do mucositis lesions around implants differ from gingivitis lesions around teeth? *J Clin Periodontol.* 2011; 38 (Suppl. 11): 182–187.
- [5] Klinge B, Hultin M, Berglundh T. Peri-implantitis. *Dent Clin North Am* 2005;49:661–76.
- [6] Berglundh T, Zitzmann NU, Donati M. Are peri-implantitis lesions different from periodontitis lesions? *J Clin Periodontol.* 2011; 38 (Suppl. 11): 188–202.
- [7] Zitzmann NU, Berglundh T. Definition and prevalence of peri-implant diseases. *J Clin Periodontol.* 2008;35(8 Suppl):286-291.
- [8] Atieh MA, Alsabeeha NH, Faggion CM Jr, Duncan WJ. The Frequency of Peri-Implant Diseases: A Systematic Review and Meta-Analysis. *J Periodontol.* 2012
- [9] Lindhe J, Meyle J. Peri-implant diseases: Consensus Report of the Sixth European Workshop on Periodontology. *J Clin Periodontol* 2008; 35 (Suppl. 8): 282–285.
- [10] Heitz-Mayfield LJ. Peri-implant diseases: diagnosis and risk indicators. *J Clin Periodontol* 2008;35(8 Suppl.):292–304.
- [11] Fransson C, Wennström J, Berglundh T. Clinical characteristics at implants with a history of progressive bone loss. *Clin Oral Impl Res* 2008;19:142-147.
- [12] Nedir R, Bischof M, Szmukler-Moncler S, Bernard JP, Samson J. Predicting osseointegration by means of implant primary stability. *Clin Oral Implants Res.* 2004;15:520-528.
- [13] Zix J, Hug S, Kessler-Liechti G, Mericske-Stern R. Measurement of dental implant stability by resonance frequency analysis and damping capacity assessment: Comparison of both techniques in a clinical trial. *Int J Oral Maxillofac Implants.* 2008;23:525-530.
- [14] Sennerby L, Meredith N. Implant stability measurements using resonance frequency analysis: Biological and biomechanical aspects and clinical implications. *Periodontol* 2000. 2008;47:51-66.
- [15] Oh JS, Kim SG, Lim SC, Ong JL. A comparative study of two noninvasive techniques to evaluate implant stability: Periotest and Osstell Mentor. *Oral Surg Oral Med Oral Pathol Oral Radiol Endod.* 2009;107:513-8.
- [16] Mombelli A, Décaillot F. The characteristics of biofilms in peri-implant disease. *J Clin Periodontol.* 2011; 38S: 203–213.

- [17] Javed F, Al-Hezaimi K, Salameh Z, Almas K, Romanos GE. Proinflammatory cytokines in the crevicular fluid of patients with peri-implantitis. *Cytokine*. 2011;53:8-12.
- [18] Froum SJ, Rosen PS. A proposed classification for peri-implantitis. *Int J Periodontics Restorative Dent*. 2012;32:533-40.
- [19] Koyanagi T, Sakamoto M, Takeuchi Y, Maruyama N, Ohkuma M, Izumi Y. Comprehensive microbiological findings in peri-implantitis and periodontitis. *J Clin Periodontol*. 2013;40:218-26.
- [20] de Freitas MM, da Silva CH, Groisman M, Vidigal GM Jr. Comparative analysis of microorganism species succession on three implant surfaces with different roughness: an in vivo study. *Implant Dent*. 2011;20:e14-23.
- [21] Fürst MM, Salvi GE, Lang NP, Persson GR. Bacterial colonization immediately after installation on oral titanium implants. *Clin Oral Implants Res*. 2007;18:501-8.
- [22] Salvi GE, Fürst MM, Lang NP, Persson GR. One-year bacterial colonization patterns of *Staphylococcus aureus* and other bacteria at implants and adjacent teeth. *Clin Oral Implants Res*. 2008;19:242-8.
- [23] Dahlén G, Wikstrom M. Occurrence of enteric rods, staphylococci and *Candida* in subgingival samples. *Oral Microbiol Immunol*. 1995;10:42-46.
- [24] Helovuoto H, Hakkarainen K, Paunio K. Changes in the prevalence of subgingival enteric rods, staphylococci and yeasts after treatment with penicillin and erythromycin. *Oral Microbiol Immunol*. 1993;8:75-79.
- [25] Fine DH. Microbial identification and antibiotic sensitivity testing, an aid for patients refractory to periodontal therapy. A report of 3 cases. *J Clin Periodontol*. 1994;21:98-106.
- [26] Rams TE, Babalola OO, Slots J. Subgingival occurrence of enteric rods, yeasts and staphylococci after systemic doxycycline therapy. *Oral Microbiol Immunol*. 1990;5:166-168.
- [27] Casado PL, Otazu IB, Balduino A, de Mello W, Barboza EP, Duarte ME. Identification of periodontal pathogens in healthy periimplant sites. *Implant Dent*. 2011;20:226-35.
- [28] Swierkot K, Lottholz P, Flores-de-Jacoby L, Mengel R. Mucositis, peri-implantitis, implant success, and survival of implants in patients with treated generalized aggressive periodontitis: 3- to 16-year results of a prospective long-term cohort study. *J Periodontol*. 2012;83:1213-25.
- [29] Mombelli A, Buser D, Lang NP. Colonization of osseointegrated titanium implants in edentulous patients. Early results. *Oral Microbiol Immunol*. 1988;3:113-20.
- [30] Mombelli A, van Oosten MA, Schurch E Jr, Land NP. The microbiota associated with successful or failing osseointegrated titanium implants. *Oral Microbiol Immunol*. 1987;2:145-51.
- [31] Becker W, Becker BE, Newman MG, Nyman S. Clinical and microbiologic findings that may contribute to dental implant failure. *Int J Oral Maxillofac Implants*. 1990;5:31-8.
- [32] Rams TE, Feik D, Slots J. Staphylococci in human periodontal diseases. *Oral Microbiol Immunol*. 1990;5:29-32.
- [33] Sanz M, Newman MG, Nachnani S, Holt R, Stewart R, Flemmig T. Characterization of the subgingival microbial flora around endosteal sapphire dental implants in partially edentulous patients. *Int J Oral Maxillofac Implants*. 1990;5:247-53.
- [34] Alcoforado GA, Rams TE, Feik D, Slots J. Microbial aspects of failing osseointegrated dental implants in humans. *J Parodontol*. 1991 Feb;10(1):11-8.
- [35] Rams TE, Roberts TW, Feik D, Molzan AK, Slots J. Clinical and microbiological findings on newly inserted hydroxyapatite-coated and pure titanium human dentalimplants. *Clin Oral Implants Res*. 1991;2:121-7.
- [36] Rosenberg ES, Torosian JP, Slots J. Microbial differences in 2 clinically distinct types of failures of osseointegrated implants. *Clin Oral Implants Res*. 1991;2:135-44.
- [37] Mombelli A, Lang NP. Antimicrobial treatment of peri-implant infections. *Clin Oral Implants Res*. 1992;3:162-8.
- [38] Kalykakis G, Zafropoulos GG, Murat Y, Hubertus S, Nisengard RJ. Clinical and microbiological status of osseointegrated implants. *J Periodontol*. 1994;65:766-70.
- [39] Augthun M, Conrads G. Microbial findings of deep peri-implant bone defects. *Int J Oral Maxillofac Implants*. 1997;12:106-12.
- [40] Danser MM, van Winkelhoff AJ, van der Velden U. Periodontal bacteria colonizing oral mucous membranes in edentulous patients wearing dental implants. *J Periodontol*. 1997;68:209-16.
- [41] Salcetti JM, Moriarty JD, Cooper LF, Smith FW, Collins JG, Socransky SS, Offenbacher S. The clinical, microbial, and host response characteristics of the failing implant. *Int J Oral Maxillofac Implants*. 1997;12:32-42.
- [42] Mombelli A, Feloutzis A, Brägger U, Lang NP. Treatment of peri-implantitis by local delivery of tetracycline. Clinical, microbiological and radiological results. *Clin Oral Implants Res*. 2001;12:287-94.
- [43] Rutar A, Lang NP, Buser D, Bürgin W, Mombelli A. Retrospective assessment of clinical and microbiological factors affecting periimplant tissue conditions. *Clin Oral Implants Res*. 2001;12:189-95.
- [44] Hultin M, Gustafsson A, Hallström H, Johansson LA, Ekfeldt A, Klinge B. Microbiological findings and host response in patients with peri-implantitis. *Clin Oral Implants Res*. 2002;13:349-58.
- [45] Leonhardt A, Dahlén G, Renvert S. Five-year clinical, microbiological, and radiological outcome following treatment of peri-implantitis in man. *J Periodontol*. 2003;74:1415-22.
- [46] Botero JE, González AM, Mercado RA, Olave G, Contreras A. Subgingival microbiota in peri-implant mucosa lesions and adjacent teeth in partially edentulous patients. *J Periodontol*. 2005;76:1490-5.
- [47] Covani U, Marconcini S, Crespi R, Barone A. Bacterial plaque colonization around dental implant surfaces. *Implant Dent*. 2006;15:298-304.
- [48] Persson GR, Salvi GE, Heitz-Mayfield LJ, Lang NP. Antimicrobial therapy using a local drug delivery system (Arestin) in the treatment of peri-implantitis. I: Microbiological outcomes. *Clin Oral Implants Res*. 2006;17:386-93.
- [49] Shibli JA, Melo L, Ferrari DS, Figueiredo LC, Faveri M, Feres M. Composition of supra- and subgingival biofilm of subjects with healthy and diseased implants. *Clin Oral Implants Res*. 2008;19:975-82.
- [50] Emrani J, Chee W, Slots J. Bacterial colonization of oral implants from nondental sources. *Clin Implant Dent Relat Res*. 2009;11:106-12.

- [51] Máximo MB, de Mendonça AC, Renata Santos V, Figueiredo LC, Feres M, Duarte PM. Short-term clinical and microbiological evaluations of peri-implant diseases before and after mechanical anti-infective therapies. *Clin Oral Implants Res.* 2009;20:99-108.
- [52] Tabanella G, Nowzari H, Slots J. Clinical and microbiological determinants of failing dental implants. *Clin Implant Dent Relat Res.* 2009;11:24-36.
- [53] Persson GR, Samuelsson E, Lindahl C, Renvert S. Mechanical non-surgical treatment of peri-implantitis: a single-blinded randomized longitudinal clinical study. II. Microbiological results. *J Clin Periodontol.* 2010;37:563-73.
- [54] Galassi F, Kaman WE, Anssari Moin D, van der Horst J, Wismeijer D, Crielaard W, Laine ML, Veerman EC, Bikker FJ, Loos BG. Comparing culture, real-time PCR and fluorescence resonance energy transfer technology for detection of *Porphyromonas gingivalis* in patients with or without peri-implant infections. *J Periodontol Res.* 2012;47:616-25.
- [55] Charalampakis G, Leonhardt Å, Rabe P, Dahlén G. Clinical and microbiological characteristics of peri-implantitis cases: a retrospective multicentre study. *Clin Oral Implants Res.* 2012;23:1045-54.
- [56] Heuer W, Kettnering A, Stumpp SN, Eberhard J, Gellermann E, Winkel A, Stiesch M. Metagenomic analysis of the peri-implant and periodontal microflora in patients with clinical signs of gingivitis or mucositis. *Clin Oral Investig.* 2012;16(3):843-50.
- [57] Ebadian AR, Kadkhodazadeh M, Zarnegarnia P, Dahlén G. Bacterial analysis of peri-implantitis and chronic periodontitis in Iranian subjects. *Acta Med Iran.* 2012;50:486-92.
- [58] Algraffee H, Borumandi F, Cascarini L. Peri-implantitis. *Br J Oral Maxillofac Surg.* 2012;50:689-94.
- [59] Renvert S, Persson GR. Periodontitis as a potential risk factor for peri-implantitis. *J Clin Periodontol.* 2009;36S:9-14.
- [60] Ong CT, Ivanovski S, Needleman IG, Retzepi M, Moles DR, Tonetti MS, Donos N. Systematic review of implant outcomes in treated periodontitis subjects. *J Clin Periodontol.* 2008;35:438-62.
- [61] Karoussis IK, Salvi GE, Heitz-Mayfield LJ, Brägger U, Hämmerle CH, Lang NP. Long-term implant prognosis in patients with and without a history of chronic periodontitis: a 10-year prospective cohort study of the ITI Dental Implant System. *Clin Oral Implants Res.* 2003;14:329-39.
- [62] Pjetursson BE, Helbling C, Weber HP, Matuliene G, Salvi GE, Brägger U, Schmidlin K, Zwahlen M, Lang NP. Peri-implantitis susceptibility as it relates to periodontal therapy and supportive care. *Clin Oral Implants Res.* 2012;23:888-94.
- [63] Heitz-Mayfield LJ, Huynh-Ba G. History of treated periodontitis and smoking as risks for implant therapy. *Int J Oral Maxillofac Implants.* 2009;24S:39-68.
- [64] De Bruyn H, Collaert B. The effect of smoking on early implant failure. *Clin Oral Implants Res.* 1994;5:260-4.
- [65] Bain CA, Moy PK. The association between the failure of dental implants and cigarette smoking. *Int J Oral Maxillofac Implants.* 1993;8:609-15.
- [66] Gorman LM, Lambert PM, Morris HF, et al. The effect of smoking on implant survival at second-stage surgery: DICRG Interim Report No. 5. Dental Implant Clinical Research Group. *Implant Dent.* 1994;3:165-8.
- [67] Carlsson GE, Lindquist L, Jemt T. Long-term marginal periimplant bone loss in edentulous patients. *Int J Prosthodontics.* 2000;13:295-302.
- [68] Esposito M, Hirsch JM, Lekholm U, Thomsen P. Biological factors contributing to failures of osseointegrated oral implants. (II). Etiopathogenesis. *Eur J Oral Sci.* 1998;106:721-64.
- [69] Haas R, Haimböck W, Mailath G, Watzek G. The relationship of smoking on peri-implant tissue: a retrospective study. *J Prosthet Dent.* 1996;76:592-6.
- [70] Haas R, Haimböck W, Mailath G, et al. The relationship of smoking on peri-implant tissue: a retrospective study. *J Prosthet Dent.* 1996;76:592-6.
- [71] Baig MR, Rajan M. Effects of smoking on the outcome of implant treatment: a literature review. *Indian J Dent Res.* 2007;18:190-5.
- [72] Ferreira SD, Silva GL, Cortelli JR, Costa JE, Costa FO. Prevalence and risk variables for peri-implant disease in Brazilian subjects. *J Clin Periodontol.* 2006;33:929-35.
- [73] Bormann KH, Stühmer C, Z'Graggen M, Kokemöller H, Rücker M, Gellrich NC. IL-1 polymorphism and periimplantitis. A literature review. *Schweiz Monatsschr Zahnmed.* 2010;120:510-20.
- [74] Huynh-Ba G, Lang NP, Tonetti MS, Zwahlen M, Salvi GE. Association of the composite IL-1 genotype with peri-implantitis: a systematic review. *Clin Oral Implants Res.* 2008;19:1154-62.
- [75] Albrektsson T, Wennerberg A. Oral implant surfaces: Part 1- review focusing on topographic and chemical properties of different surfaces and in vivo responses to them. *Int J Prosthodont.* 2004;17:536-43.
- [76] Wennerberg A, Albrektsson T. On implant surfaces: A review of current knowledge and opinions. *Oral Maxillofac Implants.* 2010;25:63-74.
- [77] Albrektsson T, Wennerberg A. Oral implant surfaces: Part 1- review focusing on topographic and chemical properties of different surfaces and in vivo responses to them. *Int J Prosthodont.* 2004;17:536-43.
- [78] Renvert S, Polyzois I, Claffey N. How do implant surface characteristics influence peri-implant disease? *J Clin Periodontol.* 2011;38 Suppl 11:214-22.
- [79] Wadhvani C, Rapoport D, La Rosa S, Hess T, Kretschmar S. Radiographic detection and characteristic patterns of residual excess cement associated with cement-retained implant restorations: a clinical report. *J Prosthet Dent.* 2012;107:151-7.
- [80] Schwarz S, Schröder C, Corcodel N, Hassel AJ, Rammelsberg P. Retrospective comparison of semipermanent and permanent cementation of implant-supported single crowns and FDPs with regard to the incidence of survival and complications. *Clin Implant Dent Relat Res.* 2012; 14 Suppl 1:e151-8.
- [81] Small BW. Cemented or screw-retained implant restorations: how do you decide? *Gen Dent.* 2011;59:14-8.
- [82] Shapoff CA, Lahey BJ. Crestal bone loss and the consequences of retained excess cement around dental implants. *Compend Contin Educ Dent.* 2012;33:94-6, 98-101.
- [83] Korsch M, Obst U, Walther W. Cement-associated peri-implantitis: a retrospective clinical observational study of fixed implant-supported restorations using a methacrylate cement. *Clin Oral Implants Res.* 2013;00:1-6.

- [84] Greenstein G, Cavallaro J. The clinical significance of keratinized gingiva around dental implants. *Compend Contin Educ Dent*. 2011;32:24-31.
- [85] Yeung SC. Biological basis for soft tissue management in implant dentistry. *Aust Dent J*. 2008;53 Suppl 1:S39-42.
- [86] Roos-Jansåker AM, Renvert H, Lindahl C, Renvert S. Nine- to fourteen-year follow-up of implant treatment. Part III: factors associated with peri-implant lesions. *J Clin Periodontol*. 2006;33:296-301.
- [87] Bouri A Jr, Bissada N, Al-Zahrani MS, Faddoul F, Nouneh I. Width of keratinized gingiva and the health status of the supporting tissues around dental implants. *Int J Oral Maxillofac Implants*. 2008;23:323-6.
- [88] Cairo F, Pagliaro U, Nieri M. Soft tissue management at implant sites. *J Clin Periodontol*. 2008;35(8 Suppl):163-7.
- [89] Carlsson GE. Dental occlusion: modern concepts and their application in implant prosthodontics. *Odontology*. 2009;97:8-17.
- [90] Misch CE, Suzuki JB, Misch-Dietsh FM, Bidez MW. A positive correlation between occlusal trauma and peri-implant bone loss: literature support. *Implant Dent*. 2005;14:108-16.
- [91] Isidor F. Influence of forces on peri-implant bone. *Clin Oral Implants Res*. 2006;17 Suppl 2:8-18.
- [92] Kim Y, Oh TJ, Misch CE, Wang HL. Occlusal considerations in implant therapy: clinical guidelines with biomechanical rationale. *Clin Oral Implants Res*. 2005;16:26-35.
- [93] Chambrone L, Chambrone LA, Lima LA. Effects of occlusal overload on peri-implant tissue health: a systematic review of animal-model studies. *J Periodontol*. 2010;81:1367-78.
- [94] Renvert S, Roos-Jansåker A-M, Claffey N. Non-surgical treatment of peri-implant mucositis and peri-implantitis: a literature review. *J Clin Periodontol*. 2008; 35 (Suppl.8):305-315.
- [95] Klinge B, Gustafsson A, Berglundh T. A systematic review of the effect of anti-infective therapy in the treatment of peri-implantitis. *J Clin Periodontol*. 2002;29 Suppl 3:213-25
- [96] Karring ES, Stavropoulos A, Ellegaard B, Karring T. Treatment of peri-implantitis by the Vector system. *Clin Oral Implants Res*. 2005;16:288-93.
- [97] Heitz-Mayfield LJ, Salvi GE, Botticelli D, Mombelli A, Faddy M, Lang NP; Implant Complication Research Group. Anti-infective treatment of peri-implant mucositis: a randomised controlled clinical trial. *Clin Oral Implants Res*. 2011;22:237-41.
- [98] van Winkelhoff AJ. Antibiotics in the treatment of peri-implantitis. *Eur J Oral Implantol*. 2012;5:S43-50.
- [99] Rams TE, Degener JE, van Winkelhoff AJ. Antibiotic resistance in human peri-implantitis microbiota. *Clin Oral Implants Res*. 2013 Apr 2. doi: 10.1111/clr.12160.
- [100] Mombelli A, Moëne R, Décaillot F. Surgical treatments of peri-implantitis. *Eur J Oral Implantol*. 2012;5:S61-70.
- [101] Mombelli A, Lang NP. Antimicrobial treatment of peri-implant infections. *Clin Oral Implants Res*. 1992;3:162-8.
- [102] Khoury F, Buchmann R. Surgical therapy of peri-implant disease: a 3-year follow-up study of cases treated with 3 different techniques of bone regeneration. *J Periodontol*. 2001;72:1498-508.
- [103] Leonhardt A, Dahlén G, Renvert S. Five-year clinical, microbiological, and radiological outcome following treatment of peri-implantitis in man. *J Periodontol*. 2003;74:1415-22.
- [104] Charalampakis G, Rabe P, Leonhardt A, Dahlén G. A follow-up study of peri-implantitis cases after treatment. *J Clin Periodontol*. 2011;38:864-71.
- [105] Heitz-Mayfield LJ, Salvi GE, Mombelli A, Faddy M, Lang NP; Implant Complication Research Group. Anti-infective surgical therapy of peri-implantitis. A 12-month prospective clinical study. *Clin Oral Implants Res*. 2012;23:205-10.
- [106] Mombelli A, Feloutzis A, Brägger U, Lang NP. Treatment of peri-implantitis by local delivery of tetracycline. Clinical, microbiological and radiological results. *Clin Oral Implants Res*. 2001;12:287-94.
- [107] Büchter A, Meyer U, Kruse-Lösler B, Joos U, Kleinheinz J. Sustained release of doxycycline for the treatment of peri-implantitis: randomised controlled trial. *Br J Oral Maxillofac Surg*. 2004;42:439-44.
- [108] Renvert S, Lessem J, Lindahl C, Svensson M. Treatment of incipient peri-implant infections using topical minocycline microspheres versus topical chlorhexidine gel as an adjunct to mechanical debridement. *J Int Acad Periodontol*. 2004;6(4 Suppl):154-9.
- [109] Renvert S, Lessem J, Dahlén G, Lindahl C, Svensson M. Topical minocycline microspheres versus topical chlorhexidine gel as an adjunct to mechanical debridement of incipient peri-implant infections: a randomized clinical trial. *J Clin Periodontol*. 2006;33:362-9.
- [110] De Araújo Nobre M, Capelas C, Alves A, Almeida T, Carvalho R, Antunes E, Oliveira D, Cardador A, Maló P. Non-surgical treatment of peri-implant pathology. *Int J Dent Hyg*. 2006;4:84-90.
- [111] Salvi GE, Persson GR, Heitz-Mayfield LJ, Frei M, Lang NP. Adjunctive local antibiotic therapy in the treatment of peri-implantitis II: clinical and radiographic outcomes. *Clin Oral Implants Res*. 2007;18:281-5.
- [112] Renvert S, Lessem J, Dahlén G, Renvert H, Lindahl C. Mechanical and repeated antimicrobial therapy using a local drug delivery system in the treatment of peri-implantitis: a randomized clinical trial. *J Periodontol*. 2008;79:836-44.
- [113] Sahn N, Becker J, Santel T, Schwarz F. Non-surgical treatment of peri-implantitis using an air-abrasive device or mechanical debridement and local application of chlorhexidine: a prospective, randomized, controlled clinical study. *J Clin Periodontol*. 2011;38:872-8.
- [114] Meyle J. Mechanical, chemical and laser treatments of the implant surface in the presence of marginal bone loss around implants. *Eur J Oral Implantol*. 2012;5Suppl:S71-81.
- [115] Schwarz F, Sculean A, Rothamel D, Schwenzer K, Georg T, Becker J. Clinical evaluation of an Er:YAG laser for nonsurgical treatment of peri-implantitis: a pilot study. *Clin Oral Implants Res*. 2005;16:44-52.
- [116] Schwarz F, Bieling K, Bonsmann M, Latz T, Becker J. Nonsurgical treatment of moderate and advanced periimplantitis lesions: a controlled clinical study. *Clin Oral Investig*. 2006;10:279-88.
- [117] Schwarz F, Bieling K, Nuesry E, Sculean A, Becker J. Clinical and histological healing pattern of peri-implantitis lesions following non-surgical treatment with an Er:YAG laser. *Lasers Surg Med*. 2006;38:663-71.
- [118] Persson GR, Roos-Jansåker AM, Lindahl C, Renvert S. Microbiologic results after non-surgical erbium-doped:yttrium, aluminum, and garnet laser or air-abrasive treatment of peri-implantitis: a randomized clinical trial. *J Periodontol*. 2011;82:1267-78.

- [119] Schwarz F, Sahm N, Iglhaut G, Becker J. Impact of the method of surface debridement and decontamination on the clinical outcome following combined surgical therapy of peri-implantitis: a randomized controlled clinical study. *J Clin Periodontol.* 2011;38:276-84.
- [120] Schwarz F, John G, Mainusch S, Sahm N, Becker J. Combined surgical therapy of peri-implantitis evaluating two methods of surface debridement and decontamination. A two-year clinical follow up report. *J Clin Periodontol.* 2012;39:789-97.
- [121] Esposito M, Grusovin MG, Worthington HV. Treatment of peri-implantitis: what interventions are effective? A Cochrane systematic review. *Eur J Oral Implantol.* 2012;5:S21-41.